



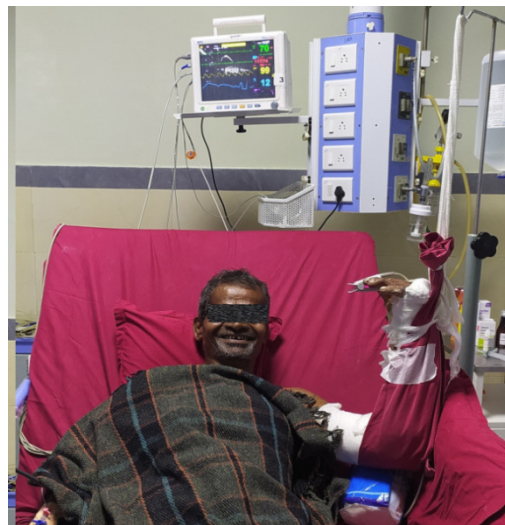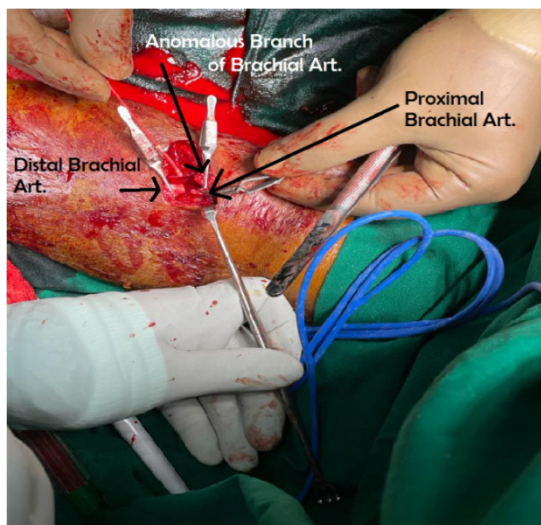
CASE REPORT

Upper Limb Neuro-Vascular Injury

A 64 year old man farmer from Nandgaon presente with history of accidental trauma to the left forearm just distally to cubital fossa by sickle while at work. He was in pain, shock and tachycardia with profusely bleeding wound, radial pulse not palpable, cold forearm and hand with delayed capillary refill time. Doppler for vascular patency of the left arm/forearm was suggestive of Tran section to brachial artery in the cubital fossa region.

Intra operatively on exploration brachial artery, anomalous branch of brachial artery and median nerve were completely transected. The vascular edges were refreshed and anastomosis done. Anomalous branch of brachial artery was damaged beyond repair and was ligated. Median nerve repaired and arm splinted above elbow. Post anastomosis good bounding radial pulse, palpable and capillary refill improved. Left radial pulse palpable, finger movement restored and saturation was 100%.

The hospital provided free treatment under MJPJAY scheme as the patient belongs to lower income class family. A noble donation from 'Bajaj Finserv' company to setup 'Cath Lab & Cardiac Theatre' made us possible to provide such type of advanced surgeries that poor patients cannot afford in a remote area of Konkan.



Dr. Amol Dharmadhikari and team

*Cardiothoracic Surgeon, MS, DNB Cardiothoracic surgery
B.K.L. Walawalkar Hospital, Dervan, Ratnagiri*