

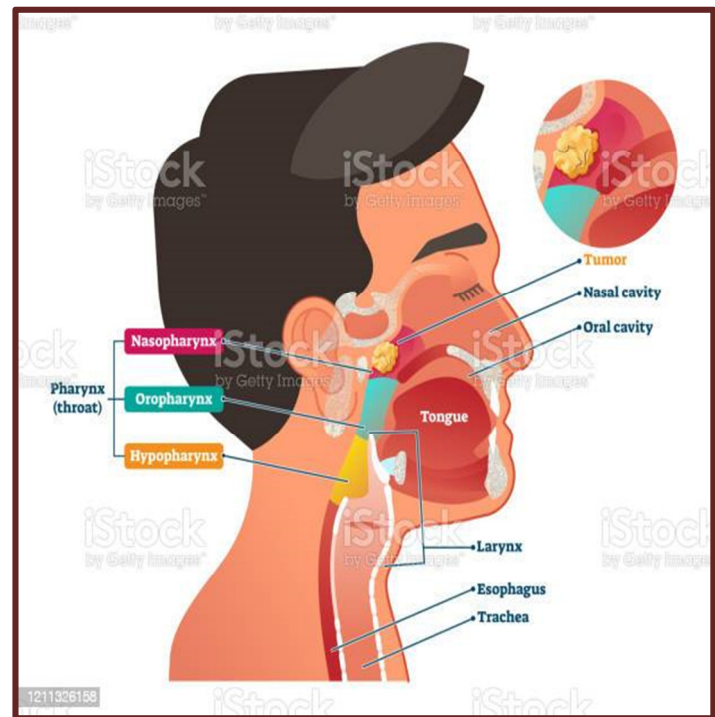
Endoscopic Nasal Angiosarcoma embolization & Resection

B. K. L. WALAWALKAR HOSPITAL, SAWARDE

Two stage Endoscopic Nasal Angiosarcoma resection in 15 years old boy for the first time in Konkan at Walawalkar hospital

It was a vascular mass originating from ® Sphenopalatine Foramen spreading to ® nasal cavity , choana , ® pterygopalatine fossa, ® Infra temporal fossa along with ® Medial & lateral pterygoid plates with ® posterior ethmoids .Most likely juvenile Nasal Angiofibrom

1. Pre- operative embolization of vascular tumor done under GA by Dr. Amit Sahu (Interventional Radiologist). B/L Internal Maxillary Artery, B/L Ascending pharyngeal Artery ® arterial vessels along with Branches from L Internal Carotid Artery Supplying the tumor embolized



2. Endoscopic Resection of the mass under GA by Dr. Sheetal Dharangutte/ Dr. Adeetya B. Varal, Dr. Digvijay A. Bandgar [ENT surgeons & team]